

66. Baugman RP, Winget DB, Lower EE: Methotrexate is steroid sparing in acute sarcoidosis: Results of a double, blind, randomized trial. *Sarcoidosis Vasc Diffuse Lung Dis* 17:60, 2000
67. Fazzi P: Pharmacotherapeutic management of pulmonary sarcoidosis. *Am J Respir Med* 2:311, 2003
68. Topalov DT, Videnovic JV, Radosavljenic TR: The long term use of methotrexate in patients with chronic disseminated sarcoidosis. *Chest* 118:245, 2000
69. Baugmann RP, Lynch JP: Difficult treatment issues in sarcoidosis. *J Intern Med* 253:41, 2003

J Oral Maxillofac Surg  
63:1021-1025, 2005

## Community Acquired Methicillin-Resistant *Staphylococcus aureus* Facial Abscesses: Case Reports

Todd G. Carter, DMD,\* Eric J. Dierks, DMD, MD, FACS,†  
Raymond Bracis, MD,‡ and O. Ross Beirne, DMD, PhD§

*Staphylococcus aureus* is a common pathogen in soft tissue maxillofacial infections. Initially this pathogen was highly susceptible to penicillin, but resistance began developing early because of the expression of penicillinase. Even the penicillinase-resistant beta-lactam antibiotics began to lose their efficacy and methicillin-resistant *Staphylococcus aureus* (MRSA) was described in 1961. MRSA infections were initially acquired nosocomially, but over time became increasingly common in the community. Review of the literature reveals a paucity of articles describing infections from this organism in the maxillofacial structures.

In 1991 Martin and Hardy<sup>1</sup> documented 2 patients with MRSA dental infections that were found to have resulted from a practitioner who did not routinely wear gloves when treating patients. These infections were a result of inoculation by the dentist. Gottlieb et al<sup>2</sup> reported 15 cases of community acquired MRSA

infection at an urban hospital over a 3-year period. However, all but 6 of these involved the ear and only 1 was a facial abscess. In 1999 Mehra et al<sup>3</sup> reported a case of MRSA-positive orbital cellulitis from an extension of a maxillary sinusitis. A case of MRSA bacterial endocarditis from a tongue piercing was reported in 2002.<sup>4</sup> Most recently, Cohen et al<sup>5</sup> reported a maxillary osteomyelitis caused by MRSA.

The oral and maxillofacial surgeon is frequently consulted by patients and other health care providers for the evaluation and treatment of facial infections. It is important to be cognizant that while common things happen commonly, one must be attentive to the possibility of atypical presentations and/or unusual pathogenic organisms. Recently the authors have noted an increasing number of facial abscesses caused by MRSA. The purpose of this article is to present 11 cases encountered by the authors over a 9-month period and describe current concepts in the management of MRSA infections in the maxillofacial region. Three representative cases are presented in detail.

### Report of Cases

#### CASE 1

A 40-year-old woman was referred to the Oral and Maxillofacial Surgery clinic from the emergency department for evaluation of a facial swelling. The patient complained of a 3-day history of increasing pain and swelling of the left oral commissure. She denied any history of trauma, dental pain, or preceding skin lesion. Her medical history was significant for depression for which she was on 2 selective serotonin reuptake inhibitors. She was afebrile and found to have an indurated and erythematous swelling of the left oral commissure. She was edentulous in both arches, and a panoramic x-ray demonstrated no intrabony pathology. She underwent incision and drainage through an intra-oral trans-

\*Formerly, Chief Resident, Oral and Maxillofacial Surgery, University of Washington, Department of Oral and Maxillofacial Surgery, Seattle, WA; Currently, Private Practice, Wailuku, HI.

†Clinical Professor of Oral and Maxillofacial Surgery, Oregon Health Sciences University, and Staff Surgeon, Legacy Emanuel Hospital, Portland, OR.

‡Clinical Professor of Infectious Diseases, Oregon Health Sciences University, and Attending Physician, Legacy Emanuel Hospital, Portland, OR.

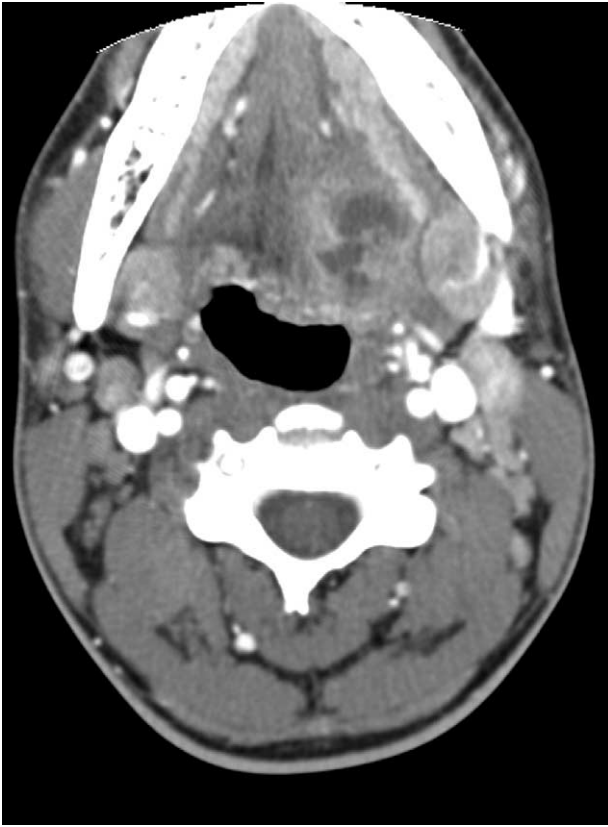§Professor and Chairman, University of Washington, Department of Oral and Maxillofacial Surgery, Seattle, WA.

Address correspondence and reprint requests to Dr Beirne: Department of Oral and Maxillofacial Surgery, Box 357134, B241 Health Sciences Center, Seattle, WA 98195; e-mail: slsb@u.washington.edu

© 2005 American Association of Oral and Maxillofacial Surgeons

0278-2391/05/6307-0022\$30.00/0

doi:10.1016/j.joms.2005.03.018



**FIGURE 1.** CT with contrast of the neck of patient No. 2 demonstrating a multiloculated fluid collection of the left sublingual space.

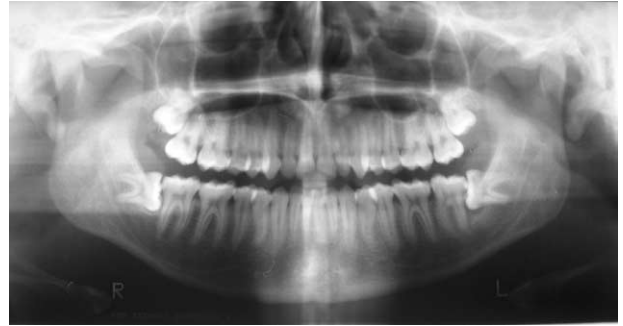
*Carter et al. Community Acquired MRSA Facial Abscesses. J Oral Maxillofac Surg 2005.*

buccal approach under local anesthesia which yielded approximately 10 cc of thick purulent exudate and a swab culture was submitted. No drain was placed and the patient was discharged with an irrigating syringe and instructions to irrigate the abscess cavity 4 to 5 times daily. She was advised to complete the antibiotic course of cephalexin prescribed in the emergency department and to follow-up in clinic as needed.

She returned to clinic the next day complaining of increased swelling. Her exam was remarkable for accumulated fibrinous debris at the incision site without significant extension of the infection. The wound was explored to insure all loculations had been lysed. Review of the culture was remarkable for 3+ MRSA with further sensitivity data pending. Linezolid 600 mg oral dose twice daily was prescribed for 10 days. She was asked to return for follow-up in 7 days. The patient did not return, and was lost to follow-up.

#### CASE 2

An 18-year-old man presented to the emergency department with a complaint of left mandibular pain and swelling as well as dysphagia. Laboratory evaluation was remarkable for a white blood cell count of 17.2, erythrocyte sedimentation rate of 55, and a C-reactive protein of 130. A computed tomography scan with contrast of the neck demonstrated a multiloculated enhancing fluid collection of the left sublingual space (Fig 1). A panoramic radiograph dem-



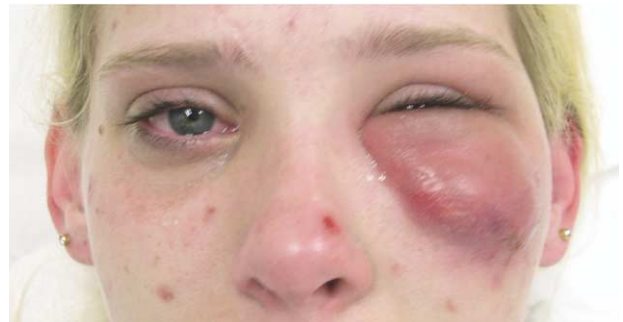**FIGURE 2.** Panoramic radiograph of patient No. 2 demonstrating horizontal impaction of bilateral mandibular third molars.

*Carter et al. Community Acquired MRSA Facial Abscesses. J Oral Maxillofac Surg 2005.*

onstrated a horizontal impaction of the lower left third molar (Fig 2). He was taken to the operating room and underwent incision and drainage of the left submandibular and sublingual spaces as well as extraction of the left upper and lower third molars. Abundant purulent material was drained and cultured. He was continued on intravenous clindamycin pending culture and sensitivity results. The patient progressed well and on postoperative day 2 microbiology confirmed 3+ MRSA. The patient was discharged on postoperative day 3 after drain removal and continued on oral clindamycin.

#### CASE 11

A 22-year-old woman presented to the emergency department with a 3-day history of increasing pain and swelling of the left cheek and lower eyelid (Fig 3). She reports having a "pimple" like lesion which she picked at and the area began to swell rapidly. She had no constitutional symptoms and no visual disturbance. Her medical history was significant for IV heroin abuse, but she denied any injections in the head and neck region. She was noted to have a large fluctuant and erythematous swelling of the left cheek and lower lid. Her visual acuity was intact and there was no evidence of retroseptal involvement. Her white blood cell count was 11.1 and she was afebrile. An incision and drainage (I&D) was performed in the emergency department and she was



**FIGURE 3.** Clinical photo of patient No. 11 demonstrating severe left periorbital abscess.

*Carter et al. Community Acquired MRSA Facial Abscesses. J Oral Maxillofac Surg 2005.*

**Table 1. CLINICAL COURSE SUMMARY OF 11 CASES OF MRSA FACIAL ABSCESS**

Patient No.	Age/Gender	Abscess Location	Treatment
1	40/F	Left oral commissure	I&D Empiric cephalixin changed to linezolid Lost to follow-up
2	18/M	Left submandibular and sublingual spaces	I&D and extraction, left upper and lower third molars IV clindamycin discharged on oral Resolved
3	52/M	Right cheek	I&D refused, expressed material cultured Clindamycin orally Lost to follow-up
4	26/M	Lower lip	I&D Penicillin empirically by ER Lost to follow-up prior to +MRSA culture
5	37/M	Left oral commissure and chin	Needle aspiration Cephalexin empirically changed to TMP-SMX Resolved
6	24/M	Left chin	I&D Cephalexin empirically Lost to follow-up prior to +MRSA culture
7	57/M	Left preauricular area	I&D, wet to dry dressings Vancomycin for concurrent MRSA pneumonia
8	37/M	Right cheek	I&D Cephalexin empirically Lost to follow-up prior to +MRSA culture
9	22/F	Left cheek	I&D Cephalexin empirically changed to TMP-SMX Resolved
10	39/M	Left cheek, left neck	I&D X2 Ampicillin/sulbactam changed to vancomycin Discharged on TMP-SMX DS
11	22/F	Left periorbital	I&D Clindamycin changed to vancomycin Discharged on TMP-SMX DS

*Carter et al. Community Acquired MRSA Facial Abscesses. J Oral Maxillofac Surg 2005.*

admitted for IV clindamycin initially. Culture returned positive for MRSA with clindamycin resistance, and she was started on vancomycin. She was discharged following drain removal after 4 days and based on sensitivity results continued on oral trimethoprim-sulfamethoxazole.

## Case Experience

Over the 9-month period from April to December of 2003, the authors encountered and treated 11 cases, at 2 separate institutions, of community acquired MRSA facial abscesses (Table 1). To determine the trends in antibiotic sensitivity, these cases were compared with all other cases of community acquired MRSA facial abscesses reported in the literature. PubMed was searched using the terms MRSA and dental, tongue, facial, abscess, and oral. A total of 4 relevant articles on MRSA maxillofacial infection were identified. These articles were then used for a citation search using Science Citation Index Expanded to

identify all reported cases of community acquired MRSA abscesses involving the maxillofacial region excluding the ear.

A total of 2 cases meeting inclusion criteria of community acquired maxillofacial abscess were identified in the literature. These 2 cases, along with the 11 cases managed by the authors, bring the total number of reported MRSA facial abscesses to 13. The cases reported by the authors represent 85% of all reported cases. All 13 MRSA facial abscesses were resistant to penicillin and cephalosporins. More extensive sensitivity data was obtained for the 11 cases reported by the authors (Table 2). Three of these cases are from 1 institution, and 8 from another. The 3 cases at institution no. 1 were all sensitive to gentamicin and tetracycline; however, these drugs were not evaluated at institution no. 2. All 11 cases for which sensitivity data reported was reported were resistant to erythromycin. Only 3 of 11 cases were

**Table 2. SUMMARY OF ANTIBIOTIC SENSITIVITY DATA**

Antibiotic Tested	Patient No.										
	1	2	3	4	5	6	7	8	9	10	11
Ampicillin/sulbactam	R	R	R	NA	NA	NA	NA	NA	NA	NA	NA
Cefazolin	R	R	R	NA	NA	NA	NA	NA	NA	NA	NA
Clindamycin	S	S	S	R	R	R	R	R	R	R	R
Erythromycin	R	R	R	R	R	R	R	R	R	R	R
Gentamicin	S	S	S	NA	NA	NA	NA	NA	NA	NA	NA
Levofloxacin	R	R	R	NA	NA	NA	NA	NA	NA	NA	NA
Penicillin	R	R	R	R	R	R	R	R	R	R	R
Tetracycline	S	S	S	NA	NA	NA	NA	NA	NA	NA	S
Trimethaprim-sulfamethoxazole	S	S	S	S	S	S	S	S	S	S	S
Oxacillin	NA	NA	NA	R	R	R	R	R	R	R	NA
Rifampin	NA	NA	NA	NA	S	NA	NA	NA	NA	NA	NA
Cephalothin	NA	NA	NA	R	R	R	R	R	R	R	R
Vancomycin	S	S	S	S	S	S	S	S	S	S	S

Carter et al. Community Acquired MRSA Facial Abscesses. J Oral Maxillofac Surg 2005.

sensitive to clindamycin. Interestingly, all cases (3/3) at institution no. 1 were sensitive to clindamycin, and all cases at institution no. 2 (8/8) were resistant. All 11 cases were sensitive to trimethaprim-sulfamethoxazole as well as vancomycin.

All abscesses with the exception of patient no. 2 were of cutaneous origin. Case 2 is, to our knowledge, the only reported case of an MRSA abscess of odontogenic origin.

## Discussion

*Staphylococcus aureus* is a coagulase-positive Gram-positive coccus, which is a normal commensal of the oral cavity. Common maxillofacial infections involving *S. aureus* include angular cheilitis and parotitis.<sup>6</sup> MRSA is frequently found as a colonizing organism in the community. These community isolates are frequently less multiply resistant to non-beta-lactam antibiotics than in typical hospital strains.<sup>7</sup>

When MRSA first appeared in tertiary hospitals it was regarded as a "cadaver marker," ie, it caused clinical infection only in the most debilitated patients. These included those with severe head injuries, quadriplegics, and the frailest elderly. Over the last decade MRSA has spread, first to the more healthy hospitalized population, and now increasingly to healthy patients with community acquired infections.

Recent evidence indicates that community MRSA strains are, in fact, microbiologically distinct. These isolates frequently carry both the SCCmec IVa and the Pantone-Valentine leukocidin alleles. It has been suggested that these alleles may confer a selective advantage over other strains and explain the high association with severe soft tissue infections.<sup>8-10</sup>

Treatment decisions for MRSA remain problematic. Vancomycin remains the drug of choice for the treatment of serious MRSA infections. In oral and maxillofacial surgery these would include those with an associated bacteremia, airway compromise, or periorbital processes. Vancomycin is a tricyclic glycopeptide that inhibits bacterial cell wall synthesis by binding to the free carboxyl end of the pentapeptide sterically inhibiting elongation. It must be administered parenterally because it is not absorbed orally. Unfortunately, it is only bacteriostatic against MRSA. It is not metabolized and is excreted renally and therefore blood levels must be checked in patients with impaired renal function to limit toxicity. Adverse effects include fever, chills, and phlebitis. Additionally hypotension and shock have been associated with histamine release from rapid administration. In the case of MRSA bacteremia, the patient should receive a minimum of 14 days of parenteral therapy because of *S. aureus*' propensity to metastasize to distant organs.

Linezolid (Zyvox, Pfizer, New York, NY) remains the alternative agent in patients with vancomycin allergy or toxicity.<sup>11</sup> It is a member of a new class of antimicrobial agents first described in 1987 known as oxazolidinones. It acts by a unique mechanism of inhibiting the formation of the 50s, 30s-mRNA, and fMet-tRNA complex in the ribosome cycle preventing the initiation of protein synthesis. Because of this unique mechanism there is no cross-resistance to other protein inhibitor antibiotics. It is bacteriostatic with similar spectrum to vancomycin, although it does have bacteriocidal activity against streptococcus species. A specific advantage of linezolid is that it is nearly 100% bioavailable with oral administration which makes it useful in the outpatient setting. It too has problems with toxicity including thrombocytopenia.

nia, anemia, and elevation of hepatic enzymes. Green discoloration of the tongue has also been associated with those drinking green tea.

Daptomycin (Cubicin, Cubist Pharmaceuticals, Lexington, MA) was recently given US Food and Drug Administration approval in 2003 for treatment of skin infections including MRSA.<sup>12</sup> It is the first cyclic lipopeptide to enter the market for treating serious bacterial infections. It acts by binding to bacterial membranes causing a rapid depolarization of membrane potential, leading to rapid cell death. It is dosed at 4 mg/kg IV daily and requires renal dosing. Unfortunately, all available data is related to in vitro activity and no clinical trial data is yet available.

The difficult task for the clinician is to decide when to initiate parenteral vancomycin or linezolid, and when to use an alternative agent. MRSA, especially the community acquired strains, are frequently sensitive to clindamycin and trimethoprim-sulfamethoxazole. The problem with these alternative agents is that MRSA develops resistance quickly, relegating these antibiotics to straight-forward abscesses not involving critical structures or the airway. Additionally, clindamycin resistance developing during treatment of erythromycin resistant strains has been reported.<sup>13</sup> In fact, the skeptic could argue that the type of infection that would qualify for these alternative agents may only need incision and drainage without antibiotic therapy. This emphasizes that the primary therapy of any abscess is adequate surgical drainage, debridement, and removal of any nidus of infection. If, however, the clinician does choose an antibiotic, it should be with the understanding that the infection will be successfully managed within 1 or 2 weeks before resistance develops. On the other hand, vancomycin should not be chosen for every MRSA infection because the broader risk of hastening the appearance of vancomycin intermediate *S. aureus*.

In our experience, there has been a profound increase in the incidence of this problem. Vancomycin

remains the drug of choice for serious MRSA infections. Based on this report, trimethoprim-sulfamethoxazole would seem an appropriate empiric therapy for suspicious MRSA infections not felt to require vancomycin. Final selection of antibiotic therapy should be based on culture and sensitivity reports. Additionally, the data indicate that there is intercommunity variability in the sensitivity to these alternative agents.

## References

1. Martin M, Hardy P: Two cases of oral infection by methicillin-resistant *Staphylococcus aureus*. *Br Dent J* 170:63, 1991
2. Gottlieb R, Shah M, Perlman D, et al: Community-acquired methicillin-resistant *Staphylococcus aureus* infections in otolaryngology. *Otolaryngol Head Neck Surg* 107:434, 1992
3. Mehra P, Caiazzo A, Bestgen S: A case report: Odontogenic sinusitis causing orbital cellulitis. *J Am Dent Assoc* 130:1086, 1999
4. Harding P, Yerkey M, Deye G, et al: Methicillin resistant *Staphylococcus aureus* (MRSA) endocarditis secondary to tongue piercing. *J Miss State Med Assoc* 43:109, 2002
5. Cohen M, Embil J, Canosa T: Osteomyelitis of the maxilla caused by methicillin-resistant *Staphylococcus aureus*. *J Oral Maxillofac Surg* 61:387, 2003
6. Smith A, Jackson M, Bagg J: The ecology of *Staphylococcus aureus* species in the oral cavity. *J Med Microbiol* 50:940, 2001
7. Hussain F, Boyle-Vavra S, Duam R: Community-acquired methicillin-resistant *Staphylococcus aureus* colonization in healthy children attending an outpatient pediatric clinic. *Pediatr Infect Dis J* 20:763, 2001
8. Naimi TS, LeDell KH, Como-Sabetti K, et al: Comparison of community- and healthcare-associated methicillin-resistant *Staphylococcus aureus* infection. *JAMA* 290:2976, 2003
9. Vandenesch F, Naimi T, Enright MC, et al: Community-acquired methicillin-resistant *Staphylococcus aureus* carrying Panton-Valentine leukocidin genes: Worldwide emergence. *Emerg Infect Dis* 9:978, 2003
10. Diep BA, Sensabaugh GF, Somboona NS, et al: Widespread skin and soft tissue infections due to two methicillin-resistant *Staphylococcus aureus* strains harboring the genes for Panton-Valentine leukocidin. *J Clin Micro* 42:2080, 2004
11. Antony S, Diaz-Vasquez E, Stratton C: Clinical experience with linezolid in the treatment of resistant gram-positive infections. *J Natl Med Assoc* 93:386, 2001
12. Hussar DA: New drugs of 2003. *J Am Pharm Assoc* 44:168, 2004
13. Frank A, Marcinak J, Mangat, P, et al: Clindamycin treatment of methicillin-resistant *Staphylococcus aureus* infections in children. *Pediatr Infect Dis J* 21:530, 2002